

**Dario Paladini**

**CURRICULUM VITAE**

*Dario Paladini*

**Prof.Dario Paladini**  
**CURRICULUM VITAE**  
**(Summary)**

- **Name:** Dario Paladini;
- **Citizenship:** Italian;
- **Date of Birth:** 17.4.1962;
- **Marital Status:** not married;
- **Languages:** Italian, English, Spanish;
- **Current position:**  
Director, Fetal Medicine and Surgery Unit – Gaslini Children’s Hospital,  
Genoa, Italy
  
- **July 1986:** **Graduation** - University Federico II of Naples (110/110 cum laude);
- **July 1987:** Educational Committee for Foreign Medical Graduates Examination (**ECFMG:** 81 Basic, 83 Clinical);
- **March 1988:** Training in *Fetal Echocardiography* - Perinatal Cardiology Unit - Guy’s Hospital - London, U.K.(3 months);
- **July 1990:** **Residency**, Dept. of Gynecology and Obstetrics - University Federico II of Naples (70/70);
- **December 1990:** **Medical Assistant** - Dept. of Gynecology and Obstetrics - University Federico II of Naples;
- **December 1990:** Training in *Surgical Gynecologic Oncology* - Gynecologic Oncology Division - National Cancer Institute of Milan, Italy (24 months);
- **September 1992:** Training in *Gynecologic Oncology* - Gynecologic Oncology Unit - Queen Elizabeth Hospital, Gateshead - Tyne & Wear, U.K.(4 months);
- **January 1993:** Training in *Surgical Gynecologic Oncology* - Gynecologic Oncology Division - National Cancer Institute of Milan, Italy (18 months);
- **Since Feb. 1994:** **Medical Assistant** - Fetal Medicine Unit and Head of the Fetal Cardiology Unit - Dept. of

Gynecology and Obstetrics - University Federico II of Naples;

- **January 2001:** **Senior Medical Assistant** - Fetal Medicine Unit and Head of the Fetal Cardiology Unit - Dept. of Gynecology and Obstetrics - University Federico II of Naples;
- **2003-2013:** **Associate Professor** - Fetal Medicine Unit and Head of the Fetal Cardiology Unit - Dept. of Gynecology and Obstetrics - University Federico II of Naples;
- **Since June 2013** Head, Fetal Medicine and Surgery Unit – Gaslini Childrens’ Hospital, Genoa, Italy

## **Titles**

**1986, July**

Graduation: 110/110 e lode.

**1987, July**

FMGEMS (Educational Committee for Foreign Medical Science).

**1990, June**

Residency in Gynecology and Obstetrics 70/70 cum laude.

**1996, April**

Diploma of Excellency in Obstetrics and Gynecology (E-EBGO)

**1998, April**

“Health Business Management” Diploma - University Federico II

## **Specialty Stages.**

**1985** (1 month)

Dept. of General Surgery - **Guy's Hospital, London, UK** (Chair: I McCall)

**1988** (4 months)

Perinatal Cardiology Dept. - **Guy's Hospital, London, UK** (Chair: Lindsay D. Allan)

**1990-92** (24 months)

Dept. of Gynecologic Oncology - **National Cancer Institute, Milan**, (Chair: Prof.F.di Re)

**1992** (6 months)

Gynaecologic Oncology Unit - **Queen Elizabeth Hospital, Newcastle, UK**  
(Chair: Prof. John M. Monaghan)

**1993-94** (18 months)

Dept of Gynecologic Oncology – **National Cancer Institute, Milan** (Chair:  
Prof. F. di Re)

**1994-2001** (6 years)

Fetal Medicine Unit - Dept Obstetrics and Gynecology – **University  
Federico II of Naples** (Chair: Prof. C. Nappi)

**2006**

Advanced training in TTTS lasering

Fetal Medicine Unit – Buzzi University Hospital, Milan (Chair:  
Prof. U. Nicolini)

Fetal Medicine Unit – Poissy University Hospital, Paris (Chair:  
Prof. Y. Ville)

**2014**

Advanced training in fetal surgery for Congenital Diaphragmatic hernia

Fetal Medicine Unit – Hospital Clinic, Barcelona (Chair: E. Gratacos)

Fetal Medicine Unit – Leuven University, Leuven (Chair: J. Deprest)

## **Scientific societies.**

Societa' Italiana di Ginecologia ed Ostetricia (**SIGO**)  
Societa' Italiana di Ecografia in Ostetricia e Ginecologia (**SIEOG**)  
Societa' Italiana di Oncologia Ginecologica (**SIOG**)  
International Society of Ultrasound in Obstetrics and Gynecology  
(**ISUOG**)  
International Gynaecologic Cancer Society (**IGCS**)  
American Institute for Ultrasound in Medicine (**AIUM**)  
Section Ecografica de la Sociedad Espanola de Ginecologia y Obstetricia  
(**SESEGO**)

## **Society appointments**

### **ISUOG**

**2003-2011** Board Member  
**Since 2004** Fetal Heart Task Force member  
**Since 2005** Editorial Board member Ultrasound Obstet Gyecol  
**2005-2008** Education Committee Chair  
**Since 2009** Education committee honorary member  
**Since 2008** Clinical Standard Committee member  
**Since 2010** Outreach committee member

### **SIEOG**

**1993-94** - regional representative  
**1995-97** - Vice-President  
**1999-00** - Secretary  
**2001-02** - Board member  
**2003-04** - Board Member  
**2007-08** – Vice-President  
**2010-13** – President  
**2013-15** - Past-President

### **SESEGO**

**Since 2005** Honorary member

**Reviewer for:**

- Am J Cardiology
- Arch Dis Child
- Eur J Obstet Gynecol Reprod Biol
- Gynecologic Oncology
- Heart
- J Ultrasound Medicine
- Obstetrics & Gynecology
- Obstetric Gynecologic Investigation
- PLOS1
- Prenatal Diagnosis
- Ultrasound in Obstet & Gynecol

## **Surgical experience:**

**1991-93** - Istituto Tumori Milano e Queen Elizabeth Hospital Gateshead, UK;

**1994-2012** Università Federico II di Napoli

**2013-2018** Ospedale IRCCS G.Gaslini di Genova

### ❖ *Gynecologic Oncology, leading surgeon:*

#### ➤ Breast cancer:

- Quadrantectomy + axillary lymphadenectomy;
- Radical Mastectomy (Patey) + axillary lymphadenectomy;
- Partial resection and biopsies;

#### ➤ Ovarian cancer:

- Staging laparotomy;
- Debulking surgery;
- Lombo-aortic and pelvic lymphadenectomy;
- Conservative surgery

#### ➤ Cervical cancer:

- Wertheim radical Hysterectomy + pelvic lymphadenectomy;\_

#### ➤ Endometrial cancer:

- Staging laparotomy;
- Simple/radical hysterectomy with node sampling/ systemic lymphadenectomy;

#### ➤ Vulvar cancer:

- Radical vulvectomy + inguinal lymphadenectomy;
- Radical hemivulvectomy + inguinal lymphadenectomy;
- Skinning vulvectomy;

### ❖ *Gynecology, leading surgeon:*

#### ➤ Benign uterine conditions:

- Simple hysterectomy, myomectomy;

#### ➤ Benign ovarian conditions:

- Simple oophorectomy, salpingectomy;

❖ *Obstetrics ,leading surgeon:*

- Elective and emergency Cesarean Section, classic and Stark techniques;
- Post-partum or Post-CS hysterectomy for placenta accreta, previa, atony;
- B-Lynch suture for uterine atony;
- Surgery for ectopic pregnancy;
- Routine D & C, and other routine labor ward procedures.



## **Fetal medicine experience:**

- ❖ Head, referral center for diagnosis of congenital anomalies
- ❖ Head, regional referral center for congenital heart disease.
- ❖ Prenatal counselling with parents.
- ❖ Long term experience with advanced targeted ultrasound
- ❖ Three-dimensional ultrasound
- ❖ Fetal echocardiography
- ❖ Fetal Neurosonography
- ❖ Invasive prenatal diagnostic procedures:
  - Amniocentesis
  - CVS
  - Cordocentesis
- ❖ Fetal surgery:
  - Placement of thoraco-amniotic shunts
  - Intra-uterine transfusions
  - Lasercoagulation for TTTS
  - Cord-clamping
  - Endotracheal plug for diaphragmatic hernia

## **Academic teaching experience and responsibility (since 2005):**

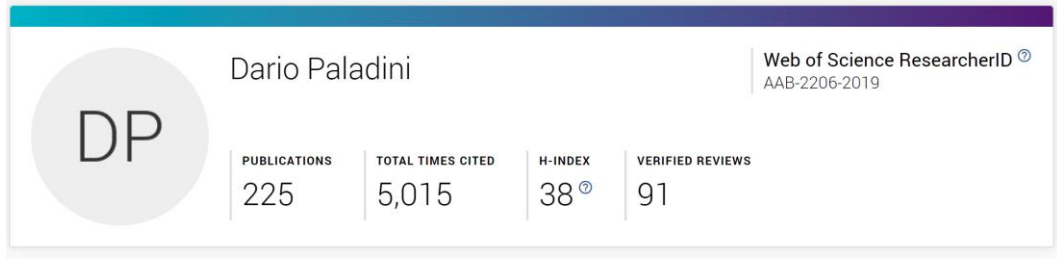
Official lessons and training in medical school graduation Ob/Gyn course;  
Official lessons and training in midwife graduation course;  
Official lessons and training for resident program;  
Post-doctoral course on Perinatal Medicine  
Training courses in OB/GYN ultrasound and in fetal echo in Italy and in several countries all over the world

## **Textbooks and manuals authorship:**

- 1) **LE CARDIOPATIE CONGENITE IN UTERO.** Ianniruberto A, *Paladini D*  
CIC Edizioni, Roma 1996.
- 2) **VIDEOATLANTE DI CARDIOLOGIA FETALE.** *Paladini D, Marasini M,*  
Volpe P. Editors. I Messaggi Editore, Bari, 2001.
- 3) **ANOMALIE FETALI IN UTERO.** *Paladini D, Volpe P.* Editors, 2004, 2010
- 4) **ULTRASOUND OF FETAL ANOMALIES** *Paladini D, Volpe P, Informa,*  
2007
- 5) **ULTRASOUND IN PREGNANCY** by *R.Romero et al.* Contribution (2  
chapters)
- 6) **ULTRASOUND OF FETAL ANOMALIES. 2<sup>ND</sup> EDITION.** *Paladini D,*  
*,Volpe P,CRC, 2014*
- 7) **MANUALE DI ECOCARDIOGRAFIA FETALE.** *Paladini D, Volpe P.*  
*Elimedica editions, 2021*

## H index (as of May 2021)

H Index secondo Web of Knowledge: 38



H Index secondo Scopus: 41

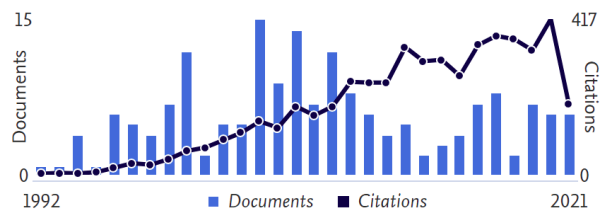
### Metrics overview

191  
Documents by author

5264  
Citations by 4519 documents

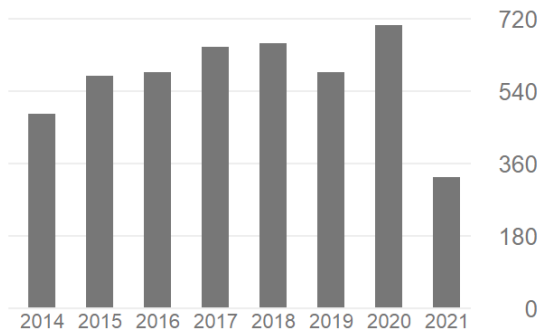
41  
h-index:

### Document & citation trends



H Index sec. Google Scholar (2021): 52

	All	Since 2016
Citations	8478	3530
h-index	52	30
i10-index	133	82



## Articles

- 1) Di Meglio A, Esposito A, *Paladini D*, Castaldi L, Di Meglio G, Di Pietto L. Integrated diagnostic techniques in the identification of ovarian malignancies. *European Journal of Gynecologic Oncology* 1988; 9(3):257.
- 2) Di Meglio A, Di Meglio G, Esposito A, *Paladini D*, Castaldi L, Ferrandino F. Echopatterns of the ovarian dermoid tumor. *European Journal of Gynecologic Oncology* 1988; 9(3):242.
- 3) Di Lieto A, Campanile M, *Paladini D*, Albano G, Paladini A. Atrial natriuretic peptide and the renin-angiotensin-aldosterone system in normotensive and hypertensive pregnancy. *Clinical and Experimental Hypertension in Pregnancy* 1988;B7(1&2):89.
- 4) Martinelli P, *Paladini D*, Nicotra A, Guerritore T. In utero diagnosis of oropharyngeal teratoma. A case report. *European Journal of Obstetrics, Gynecology and Reproductive Biology* 1990; 35:291.
- 5) Martinelli P, *Paladini D*, Nicotra A, Russo R, D'Armiento MR. Holocardius: antenatal diagnosis and pathogenetic evaluation. *European Journal of Obstetrics, Gynecology and Reproductive Biology* 1990; 36:153.
- 6) *Paladini D*, Chita S, Allan LD. Prenatal measurement of cardio-thoracic ratio in evaluation of heart disease. *Archives of Disease in Childhood* 1990; 65:20.
- 7) *Paladini D*, Di Meglio A, Esposito A, Di Meglio G, Riccio A. Ultrasonic features of an ovarian cystohemangioma. *European Journal of Obstetrics, Gynecology and Reproductive Biology* 1991; 40:239.
- 8) Fontanelli R, *Paladini D*, Raspagliesi F. The role of appendectomy in staging procedures for ovarian cancer. *Gynecologic Oncology* 1992; 46:42-44.
- 9) *Paladini D*, Calabro' R, Palmieri S, D'Andrea T. Prenatal diagnosis of congenital heart disease and fetal karyotyping. *Obstetrics & Gynecology* 1993; 81:679-82.
- 10) Pacileo G, *Paladini D*, Pisacane C, Palmieri S, Russo MG, Calabrò R. Role of changing loading conditions on atrio-ventricular flow velocity patterns in normal human fetuses. *Am J Cardiol* 1994; 73:991-3.

- 11) di Re F, *Paladini D*, Fontanelli R, Feudale A, Raspagliesi F. Surgical staging for epithelial ovarian tumors of low malignant potential. *Int J Gynecol Cancer* 1994; 4:310-14.
- 12) *Paladini D*, Fontanelli R, Raspagliesi F, Ntousias V. Intestinal operations during surgical procedures for epithelial ovarian cancer. *Int J Gynecol Cancer* 1994; 4:320-23.
- 13) Pacileo G, *Paladini D*, Palmieri S, Pisacane C, Russo MG, Calabrò R. Echocardiographic assessment of diastolic function in normal human fetuses. *J Perinat Med* 1994; 22 (Suppl.1):43-45.
- 14) *Paladini D*, Cross P, Lopes A, Monaghan JM. Prognostic significance of lymph-node variables in squamous cell carcinoma of the vulva. *Cancer* 1994; 74:2491-96.
- 15) *Paladini D*, Raspagliesi F, Fontanelli R, Ntousias V. Radical surgery after induction chemotherapy in locally advanced cervical cancer. A feasibility study. *Int J Gynecol Cancer* 1995; 5:296-300.
- 16) *Paladini D*, Palmieri S, Russo MG, Pacileo G. Cardiac multiple rhabdomyomatosis. Prenatal diagnosis and natural history. *Ultrasound Obstet Gynecol* 1995; 7(1):137-8.
- 17) *Paladini D*, Palmieri S, Morelli PM, Forleo F, Morra T, Salviati M, Zampella C, D'Angelo A, Martinelli P. Fetal inguino-scrotal hernia: prenatal ultrasound diagnosis and pathogenetic evaluation. *Ultrasound Obstet Gynecol* 1996; 7(2):145-6.
- 18) *Paladini D*, Palmieri S, Lecora M, Perone L, Di Meglio A, D'Armiento MR, Cascioli C, Martinelli P. Prenatal ultrasound diagnosis of Roberts syndrome in a family with negative history. *Ultrasound Obstet Gynecol* 1995; 7:208-10.
- 19) Lupi G, Raspagliesi F, Zucali R, Fontanelli R, *Paladini D*, Kenda R, di Re F. Combined pre-operative chemo-radiotherapy followed by radical surgery in locally advanced vulvar carcinoma. A pilot study. *Cancer* 1996; 77:1472-8.
- 20) *Paladini D*, Palmieri S, D'Angelo A, Martinelli P. Prenatal ultrasound diagnosis of cerebral artero-venous fistola. *Obstet Gynecol* 1996; 88:34-6.
- 21) *Paladini D*, Rustico MA, Todros T, Palmieri S, Gaglioti P, Benetton A. Conotruncal anomalies in prenatal life. *Ultrasound Obstet Gynecol* 1996; 8:241-6.

- 22) *Paladini D*, Russo MG, Palmieri S, et al. Myocardial displasia in a 3<sup>RD</sup> trimester fetus. *Texas Heart Inst J* 1997; 24:53-7.
- 23) Grandone E, Margaglione M, Colaizzao D, Cappucci G, *Paladini D*, et al. Factor V Leiden, C>T MTHFR polymorphism and genetic susceptibility to preeclampsia. *Thrombosis & Haemostasis* 1997; 77:1052-4.
- 24) Martinelli P, *Paladini D*, D'Armiento MR, Scarano G. Prenatal diagnosis of cloverleaf skull in the subtype 2 Pfeiffer syndrome. Letter to the editor. *Clinical Dysmorphol* 1997; 6:89-90.
- 25) *Paladini D*, Palmieri S, Celentano E, et al. Pulmonary venous blood flow in the human fetus. *Ultrasound in Obstet Gynecol* 1997; 10:1-5.
- 26) Raspagliesi F, Fontanelli R, *Paladini D*, di Re E. Conservative surgery in "high risk" epithelial ovarian carcinoma. *J Am Coll Surgeons* 1997; 185:457-60.
- 27) *Paladini D*, Pacileo G, Palmieri S, et al. Prenatal diagnosis of 22q11 microdeletion in a fetus with a conotruncal heart defect. *Ultrasound in Obstet & Gynecol* 1998; 11:68-70.
- 28) *Paladini D*, Morra T, Guida F, et al. Prenatal diagnosis and perinatal management of a lingual lymphangioma. *Ultrasound in Obstet & Gynecol* 1998; 11:141-3.
- 29) *Paladini D*, Morra T, Teodoro A, et al. Prenatal diagnosis and hemodynamic evaluation of Klippel-Trenaunay-Weber syndrome. *Ultrasound in Obstet & Gynecol* 1998; 11:215-17.
- 30) *Paladini D*, Russo MG, Palmieri S, et al. Prenatal diagnosis of aortic insufficiency. *Ultrasound in Obstet & Gynecol* 1998; 11:355-57.
- 31) *Paladini D*, Morra T, Teodoro A, et al. Prenatal diagnosis of micrognathia in the fetus. The jaw index. *Obstet Gynecol* 1999; 93:382-6.
- 32) *Paladini D*, D'Agostino A, Liguori M, et al. Prenatal findings in trisomy 16q. *Pren Diagnosis* 1999; 19:472-5.
- 33) Grandone E, Margaglione M, Colaizzo D, Cappucci G, Sciannammè, Mantanaro S, *Paladini D*, Martinelli P, Di Minno G. Prothrombotic genetic risk factors and the occurrence of gestational hypertension with or without proteinuria. *Thromb Haemost* 1999; 81: 349-52.
- 34) *Paladini D*. Prenatal screening of congenital heart disease between ethics and cost-effectiveness. Time for a change in current prenatal ultrasound screening policies?- *Editorial Ultrasound Obstet Gynecol* 1999; 14: 225-8.

- 35) *Paladini D, Tartaglione A, Agangi A, et al.* The association between congenital heart disease and Down syndrome in prenatal life. *Ultrasound Obstet Gynecol* 2000; 15: 104-8.
- 36) *Paladini D, D'Armiento M, Ardovino I, Martinelli P.* Prenatal diagnosis of the cerebro-oculo-facio-skeletal (COFS) syndrome. *Ultrasound Obstet Gynecol* 2000; 16: 91-3.
- 37) *Paladini D, Lamberti A, Agangi A, Martinelli P.* Cleido-cranial dysostosis. Prenatal diagnosis of a late onset form. *Ultrasound Obstet Gynecol* 2000; 16: 100-1.
- 38) *Castaldo G, Martinelli P, Massa C, Fuccio A, Grosso M, Rippa E, Paladini D, Salvatore F.* Prenatal diagnosis of cystic fibrosis: a case of twin pregnancy diagnosis and a review of 5 years' experience. *Clin Chim Acta* 2000; 298:121-33.
- 39) *Paladini D, Borghese A, Arienzo M, Teodoro A, Martinelli P, Nappi C.* Prospective ultrasound diagnosis of Pallister-Killian syndrome in the second trimester of pregnancy: the importance of the facial fetal profile. *Prenat Diagnosis* 2000; 20:996-8.
- 40) *Paladini D, Palmieri S, Lamberti A, Teodoro A, Martinelli P, Nappi C.* Characterization and natural history of ventricular septal defects in the fetus. *Ultrasound Obstet Gynecol.* 2000 Aug;16(2):118-22. PubMed PMID: 11117079.
- 41) *Pacileo G, Paladini D, Russo MG, Pisacane C, Santoro G, Calabro R.* Echocardiographic assessment of ventricular filling pressure during the second and third trimester of gestation. *Ultrasound Obstet Gynecol* 2000; 16:128-32.
- 42) *Monni G, Paladini D, Ibba RM, Teodoro A, Zoppi MA, Lamberti A, Floris M, Putzolu, M, Martinelli P.* Prenatal ultrasound diagnosis of congenital cystic adenomatoid malformation of the lung: a report of 26 cases and review of the literature. *Ultrasound Obstet Gynecol* 2000; 16:159-62.
- 43) *Raspagliesi F, Ditto A, Paladini D, Fontanelli R, Stefanon B, Dipalma S, De Palo G.* Prognostic indicators in melanoma of the vulva. *Ann Surg Oncol* 2000; 7:738-42.
- 44) *Paladini D, Lamberti A, Teodoro A, Arienzo M, Tartaglione A, Martinelli P.* Tissue Doppler imaging of the fetal heart. *Ultrasound Obstet Gynecol* 2000; Nov:530-5.

- 45) *Paladini D*, Tartaglione A, Agangi A, Foglia S, Martinelli P, Nappi C. Pena-Shokeir phenotype with variable onset in three consecutive pregnancies. *Ultrasound Obstet Gynecol* 2001; 17:163-5.
- 46) Grandone E, Margaglione M, Colaizzo D, Pavone G, *Paladini D*, Martinelli P, Di Minno G. Lower birth weight in neonates of mothers carrying factor V G1691A and factor II. *Haematologica* 2002 Feb; 87(2):177-81.
- 47) Martinelli P, Grandone E, Colaizzo D, *Paladini D*, Sciannone N, Margaglione M, Di Minno G. Familial thrombophilia and the occurrence of fetal growth restriction. *Haematologica* 2001; 86:428-31.
- 48) Martinelli P, Russo R, Agangi A, *Paladini D*. Prenatal ultrasound diagnosis of frontonasal displasia. *Prenat Diagn* 2002; 22:375-9.
- 49) *Paladini D*, Russo MG, Vassallo M, Tartaglione A, Pacileo G, Martinelli P, Calabro R. Ultrasound evaluation of aortic valve anatomy in the fetus. *Ultrasound Obstet Gynecol* 2002; 20:30-4.
- 50) *Paladini D*, Russo M, Teodoro A, Pacileo G, Capozzi G, Martinelli P, Nappi C, Calabro R. Prenatal diagnosis of congenital heart disease in the Naples area during the years 1994-1999 – The experience of a joint fetal-pediatric cardiology unit. *Prenat Diagn* 2002 Jul; 22(7):545-52.
- 51) *Paladini D*, Russo MG, Tartaglione A, Loffredo A, Martinelli P. Prenatal ultrasound diagnosis of Toriello-Carey syndrome. *Prenat. Diagn.* 2002 Dec; 22(13):1185-87.
- 52) *Paladini D*, Tartaglione A, Lamberti A, Lapadula C, Martinelli P. Prenatal ultrasound diagnosis of Nager syndrome. *Ultrasound Obstet Gynecol.* 2003 Feb; 21(2):195-7.
- 53) Todros T, *Paladini D*, Chiappa E, Russo MG, Gaglioti P, Pacileo G, Cau MA, Martinelli P. Pulmonary stenosis and atresia with intact ventricular septum during prenatal life. *Ultrasound Obstet Gynecol.* 2003 Mar; 21(3):228-33.
- 54) *Paladini D*, Tartaglione A, Vassallo M, Martinelli P. Prenatal ultrasonographic findings of a cardiac myxoma. *Obstet Gynecol* 2003 Nov; 102(5 Pt2):1174-6.
- 55) Volpe P, *Paladini D*, Marasini M, Buonadonna AL, Russo MG, Caruso G, Marzullo G, Vassallo M, Martinelli P, Gentile M. Common arterial trunk in the fetus: characteristics, associations, and outcome in a multicenter series of 23 cases. *Heart* 2003 Dec; 89(12):1437-41.



- 56) Greco L, Veneziano A, Di Donato L, Zampella C, Pecoraro M, *Paladini D*, Paparo F, Vollaro A, Martinelli P. Undiagnosed coeliac disease does not appear to be associated with unfavourable outcome of pregnancy. *Gut* 2004 Jan; 53(1):149-51.
- 57) *Paladini D*, Russo MG, Vassallo M, Tartaglione A. The “in-plane” view of the inter-ventricular septum. A new approach to the characterization of ventricular septal defects in the fetus. *Prenat. Diagn.* 2003 Dec 30;23(13):1052-5.
- 58) Chiaffarino F, Parazzini F, *Paladini D*, Acaia B, Ossola W, Marozio L, Facchinetti F, Del Giudice A. A small randomised trial of low-dose aspirin in women at high risk of pre-eclampsia. *Eur J Obstet Gynecol Reprod Biol* 2004 Feb 10; 112(2):142-4.
- 59) Maruotti GM, *Paladini D*, Aganti A, Martinelli P. Prospective prenatal diagnosis of Fraser syndrome variant in a family with negative history. *Prenat. Diagn.* 2004 Jan; 24(1):69-70.
- 60) *Paladini D*, Vassallo M, Tartaglione A, Lapadula C, Martinelli P. The role of tissue harmonic imaging in fetal echocardiography. *Ultrasound Obstet Gynecol* 2004 Feb; 23(2):159-64.
- 61) *Paladini D*, Vassallo M, D’Armiento MR, Cianciaruso B, Martinelli P. Prenatal detection of multiple fetal anomalies following inadvertent exposition to cyclophosphamide in the first trimester of pregnancy. *Birth Defects Res A Clin Mol Teratol* 2004 Feb; 70(2):99-100.
- 62) *Paladini D*, Foglia S, Sglavo G, Martinelli P. Congenital constriction band of the upper arm: the role of three-dimensional ultrasound in diagnosis, counseling and multidisciplinary consultation. *Ultrasound Obstet Gynecol* 2004 May; 23(5):520-2.
- 63) Martinelli P, Maruotti GM, Pasquali D, *Paladini D*, Aganti A, Ripa E, Colantuoni V, Bellastella A, Sinisi AA. Genetic prenatal RET testing and pregnancy management of multiple endocrine neoplasia Type II A (MEN2A): a case report. *J Endocrinol Invest* 2004 Apr; 27(4):357-60.
- 64) Martinelli P, Maruotti GM, Agangi A, Mazzarelli LL, Bifulco G, *Paladini D*. Prenatal diagnosis of hemifacial microsomia and ipsilateral cerebellar hypoplasia in a fetus with oculoauriculovertebral spectrum. *Ultrasound Obstet Gynecol* 2004 Aug; 24(2):199-201.
- 65) Volpe P, *Paladini D*, Marasini M, Buonadonna AL, Russo MG, Caruso G, Marzullo A, Arciprete P, Martinelli P, Gentile M. Characteristics, associations and outcome of absent pulmonary valve syndrome in the fetus. *Ultrasound Obstet Gynecol* 2004 Nov; 24(6):623-8.

- 66) *Paladini D, Volpe P, Russo MG, Vassallo M, Sglavo G, Gentile M.* Aortic coarctation: prognostic indicators of survival in the fetus. *Heart* 2004 Nov; 90(11):1348-9.
- 67) *Paladini D, D'Armiento MR, Martinelli P.* Prenatal ultrasound diagnosis of poland syndrome. *Obstet Gynecol* 2004 Nov; 104(5 Pt 2):1156-9;
- 68) *Martinelli P, Martinelli V, Agangi A, Maruotti GM, Paladini D, Ciancia R, Rotoli B.* Interferon alfa treatment for pregnant women affected by essential thrombocythemia: case reports and a review. *Am J Obstet Gynecol* 2004 Dec; 191(6):2016-20.
- 69) *Falcidia E, Parano E, Grillo A, Pavone P, Takabayashi H, Trifiletti RR, Scollo P, Dallapiccola B, Grammatico P, Novelli A, Paladini D, Monni G, Gulisano A, Scassellati G.* Fetal Cells in Maternal Blood: A Six-Fold Increase in Women who have Undergone Amniocentesis and Carry a Fetus with Down Syndrome: A Multicenter Study. *Neuropediatrics* 2004 Dec; 35(6):321-4.
- 70) *Genesio R, De Brasi D, Conti A, Borghese A, Di Micco P, Di Costanzo P, Paladini D, Ungaro P, Nitsch L.* Inverted duplication of 15q with terminal deletion in a multiple malformed newborn with intrauterine growth failure and lethal phenotype. *Am J Med Genet A.* 2004 Aug 1;128(4):422-8. Erratum in: *Am J Med Genet A.* 2005 Jul 1;136(1):113.
- 71) *Romeo E, D'Alto M, Russo MG, Sarubbi B, Cardaropoli D, Paladini D, Pacileo G, Annunziata A, Calabro R.* Fetal supraventricular tachycardia diagnosed and treated at twenty-four weeks of gestation and after birth: a case report. *Ital Heart J.* 2004 Oct;5(10):777-80.
- 72) *Agangi A, Paladini D, Bagolan P, Maruotti GM, Martinelli P.* Split notochord syndrome variant: prenatal findings and neonatal management. *Prenat Diagn.* 2005 Jan;25(1):23-7. Review.
- 73) *Paladini D, Marasini M, Volpe P.* Severe ductal constriction in the third-trimester fetus following maternal self-medication with nimesulide. *Ultrasound Obstet Gynecol.* 2005 Apr;25(4):357-61.
- 74) *Paladini D, Vassallo M, Sglavo G, Russo MG, Martinelli P.* Diagnosis and outcome of congenital heart disease in fetuses from multiple pregnancies. *Prenat Diagn.* 2005 May;25(5):403-6.
- 75) *Paladini D, Caruso G, Sglavo G, Lapadula C, Parisi G, Martinelli P.* Hypoplastic left heart syndrome associated with left ventricle-coronary artery-pulmonary artery fistula: prenatal diagnosis and histological correlation. *Ultrasound Obstet Gynecol.* 2005 Jul;26(1):78-80.

- 76) *Paladini D, Rustico M, Viora E, Giani U, Bruzzese D, Campogrande M, Martinelli P.* Fetal size charts for the Italian population. Normative curves of head, abdomen and long bones. *Prenat Diagn.* 2005 Jun;25(6):456-64.
- 77) *Paladini D, Vassallo M, Sglavo G, Lapadula C, Longo M, Nappi C.* Cavernous lymphangioma of the face and neck: prenatal diagnosis by three-dimensional ultrasound. *Ultrasound Obstet Gynecol.* 2005 Sep;26(3):300-2.
- 78) *Di Salvo G, Russo MG, Paladini D, Pacileo G, Felicetti M, Ricci C, Cardaropoli D, Palma M, Caso P, Calabro R.* Quantification of regional left and right ventricular longitudinal function in 75 normal fetuses using ultrasound-based strain rate and strain imaging. *Ultrasound Med Biol.* 2005 Sep;31(9):1159-62.
- 79) *Paladini D, Sglavo G, Quarantelli M, D'armiento MR, Martinelli P, Salvatore M.* Large infratentorial subdural hemorrhage diagnosed by ultrasound and MRI in a second-trimester fetus. *Ultrasound Obstet Gynecol.* 2005 Dec;26(7):789-91; discussion 791.
- 80) *Grandone E, Corrao AM, Colaizzo D, Vecchione G, Di Girgenti C, Paladini D, Sardella L, Pellegrino M, Zelante L, Martinelli P, Margaglione M.* Homocysteine metabolism in families from southern Italy with neural tube defects: role of genetic and nutritional determinants. *Prenat Diagn.* 2006 Jan;26(1):1-5.
- 81) *Maruotti GM, Agangi A, Martinelli P, Paladini D.* Early prenatal diagnosis of concordant posterior urethral valves in male monochorionic twins. *Prenat Diagn.* 2006 Jan;26(1):67-70.
- 82) *Valentin L, Ameye L, Testa A, Lecuru F, Bernard JP, Paladini D, Van Huffel S, Timmerman D.* Ultrasound characteristics of different types of adnexal malignancies. *Gynecol Oncol.* 2006 Jul;102(1):41-8.
- 83) *Paladini D, Volpe P, Marasini M, Russo MG, Vassallo M, Gentile M, Calabro R.* Diagnosis, characterization and outcome of congenitally corrected transposition of the great arteries in the fetus: a multicenter series of 30 cases. *Ultrasound Obstet Gynecol.* 2006 Mar;27(3):281-5.
- 84) *Todros T, Verdiglione P, Ogge G, Paladini D, Vergani P, Cardaropoli S.* Low incidence of hypertensive disorders of pregnancy in women treated with spiramycin for toxoplasma infection. *Br J Clin Pharmacol.* 2006 Mar;61(3):336-40.
- 85) *Vassallo M, Pascotto M, Pisacane C, Santoro G, Paladini D, Russo MG, Calabro R.* Right superior vena cava draining into the left atrium: prenatal

- diagnosis and postnatal management. *Ultrasound Obstet Gynecol.* 2006 Apr; 27(4):445-8.
- 86) *Paladini D, Volpe P.* Posterior fossa and vermian morphometry in the characterization of fetal cerebellar abnormalities: a prospective three-dimensional ultrasound study. *Ultrasound Obstet Gynecol.* 2006 May;27(5):482-9.
- 87) *Paladini D, Vassallo M, Sglavo G, Lapadula C, Martinelli P.* The role of spatio-temporal image correlation (STIC) with tomographic ultrasound imaging (TUI) in the sequential analysis of fetal congenital heart disease. *Ultrasound Obstet Gynecol.* 2006 May;27(5):555-61.
- 88) *Volpe P, Paladini D, Resta M, Stanziano A, Salvatore M, Quarantelli M, De Robertis V, Buonadonna AL, Caruso G, Gentile M.* Characteristics, associations and outcome of partial agenesis of the corpus callosum in the fetus. *Ultrasound Obstet Gynecol.* 2006 May;27(5):509-16.
- 89) *Cardaropoli D, Russo MG, Paladini D, Pisacane C, Caputo S, Giliberti P, Calabro R.* Prenatal echocardiography in a case of Uhl's anomaly. *Ultrasound Obstet Gynecol.* 2006 Jun;27(6):713-4.
- 90) *Martinelli P, Maruotti GM, Coppola A, Agangi A, Paladini D, Grandone E, Di Minno G.* Pregnancy in a woman with a history of Budd-Chiari syndrome treated by porto-systemic shunt, protein C deficiency and bicornuate uterus. *Thromb Haemost.* 2006 Jun;95(6):1033-4.
- 91) *Fortunato G, Carandente Giarrusso P, Martinelli P, Sglavo G, Vassallo M, Tomeo L, Rea M, Paladini D.* Cardiac troponin T and amino-terminal pro-natriuretic peptide concentrations in fetuses in the second trimester and in healthy neonates. *Clin Chem Lab Med.* 2006;44(7):834-6.
- 92) *Grandone E, Colaizzo D, Martinelli P, Paladini D, di Minno G, Margaglione M.* Adverse outcome in women with thrombophilia and bilateral uterine artery notches. *Fertil Steril.* 2006 Jul 6.
- 93) *D'alto M, Russo MG, Pacileo G, Paladini D, Romeo E, Sarubbi B, Cardaropoli D, Ricci C, Calabro R.* Left ventricular remodelling in outflow tract obstructive lesions during fetal life. *J Cardiovasc Med (Hagerstown).* 2006 Oct;7(10):726-730.
- 94) *Paladini D, Maruotti GM, Sglavo G, Fratellanza G, Quarantelli M, Martinelli P.* Massive fetal hemorrhage and fetomaternal alloimmune thrombocytopenia from human platelet antigen 5b incompatibility: an unusual association. *Ultrasound Obstet Gynecol.* 2007 Apr; 29(4):471-4.

- 95) *Paladini D*. Standardisation of onscreen fetal heart orientation prior to storage of Spatio-Temporal Image correlation volume datasets. *Editorial*. *Ultrasound Obstet Gynecol*, 2007; 29:605-11.
- 96) *Paladini D*, Maruotti GM, Sglavo , Penner I, Leone F, D'armiento MR, Martinelli P. Diagnosis of Femoral-hypoplasia unusual facies syndrome in the fetus. *Ultrasound Obstet Gynecol*, 2007
- 97) *Paladini D*, Sglavo G, Penner I, Pastore G, Nappi C. Fetuses with Down syndrome have an enlarged anterior fontanelle in the second trimester of pregnancy. *Ultrasound Obstet Gynecol*. 2007 Nov;30(6):824-9. PubMed PMID: 17803259.
- 98) D'Alto M, Russo MG, *Paladini D*, Di Salvo G, Romeo E, Ricci C, Felicetti M, Tartaglione A, Cardaropoli D, Pacileo G, Sarubbi B, Calabrò R. The challenge of fetal dysrhythmias: echocardiographic diagnosis and clinical management. *J Cardiovasc Med (Hagerstown)*. 2008 Feb;9(2):153-60. PubMed PMID: 18192808.
- 99) *Paladini D*, Volpe P, Sglavo G, Vassallo M, De Robertis V, Marasini M, Russo MG. Transposition of the great arteries in the fetus: assessment of the spatial relationships of the arterial trunks by four-dimensional echocardiography. *Ultrasound Obstet Gynecol*. 2008 Mar;31(3):271-6. PubMed PMID: 18307212.
- 100) Timmerman D, Testa AC, Bourne T, Ameye L, Jurkovic D, Van Holsbeke C, *Paladini D*, Van Calster B, Vergote I, Van Huffel S, Valentin L. Simple ultrasound-based rules for the diagnosis of ovarian cancer. *Ultrasound Obstet Gynecol*. 2008 Jun;31(6):681-90.
- 101) *Paladini D*, Vassallo M, Sglavo G, Nappi C. Struma ovarii associated with hyperthyroidism, elevated CA 125 and pseudo-Meigs syndrome may mimic advanced ovarian cancer. *Ultrasound Obstet Gynecol*. 2008 Aug;32(2):237-8.
- 102) Lee W, Allan L, Carvalho JS, Chaoui R, Copel J, Devore G, Hecher K, Munoz H, Nelson T, *Paladini D*, Yagel S; ISUOG Fetal Echocardiography Task Force. ISUOG consensus statement: what constitutes a fetal echocardiogram? *Ultrasound Obstet Gynecol*. 2008 Aug;32(2):239-42. PubMed PMID: 18663769.
- 103) Savelli L, Testa AC, Timmerman D, *Paladini D*, Ljungberg O, Valentin L. Imaging of gynecological disease (4): clinical and ultrasound characteristics of struma ovarii. *Ultrasound Obstet Gynecol*. 2008 Aug;32(2):210-9.

- 104) Russo MG, *Paladini D*, Pacileo G, Ricci C, Di Salvo G, Felicetti M, Di Pietto L, Tartaglione A, Palladino MT, Santoro G, Caianiello G, Vosa C, Calabrò R. Changing spectrum and outcome of 705 fetal congenital heart disease cases: 12 years, experience in a third-level center. *J Cardiovasc Med (Hagerstown)*. 2008 Sep;9(9):910-5.
- 105) *Paladini D*, Vassallo M, Sglavo G, Pastore G, Lapadula C, Nappi C. Normal and abnormal development of the fetal anterior fontanelle: a three-dimensional ultrasound study. *Ultrasound Obstet Gynecol*. 2008 Nov;32(6):755-61. Erratum in: *Ultrasound Obstet Gynecol*. 2009 Mar;33(3):370.
- 106) Di Salvo G, Russo MG, *Paladini D*, Felicetti M, Castaldi B, Tartaglione A, di Pietto L, Ricci C, Morelli C, Pacileo G, Calabrò R. Two-dimensional strain to assess regional left and right ventricular longitudinal function in 100 normal fetuses. *Eur J Echocardiogr*. 2008 Nov;9(6):754-6. Epub 2008 Apr 28.
- 107) *Paladini D*, Sglavo G, Greco E, Nappi C. Cardiac screening by STIC: can sonologists performing the 20-week anomaly scan pick up outflow tract abnormalities by scrolling the A-plane of STIC volumes? *Ultrasound Obstet Gynecol*. 2008 Dec;32(7):865-70.
- 108) Guida M, *Paladini D*, Greco E, Di Spiezio Sardo A, Coppola C, Nappi C. Pregnancy-induced symptomatic pelvic and extra-pelvic cavernous hemangiomas. *Clin Exp Obstet Gynecol*. 2009;36(1):55-7.
- 109) Napolitano R, Maruotti GM, Quarantelli M, Martinelli P, *Paladini D*. Prenatal diagnosis of Seckel Syndrome on 3-dimensional sonography and magnetic resonance imaging. *J Ultrasound Med*. 2009 Mar;28(3):369-74.
- 110) Greco E, Sglavo G, *Paladini D*. Prenatal sonographic diagnosis of Rubinstein-Taybi syndrome. *J Ultrasound Med*. 2009 May;28(5):669-72.
- 111) *Paladini D*. Sonography in obese and overweight pregnant women: clinical, medicolegal and technical issues. *Ultrasound Obstet Gynecol*. 2009 Jun;33(6):720-9. Review.
- 112) *Paladini D*, Testa A, Van Holsbeke C, Mancari R, Timmerman D, Valentin L. Imaging in gynecological disease (5): clinical and ultrasound characteristics in fibroma and fibrothecoma of the ovary. *Ultrasound Obstet Gynecol*. 2009 Aug;34(2):188-95.
- 113) *Paladini D*, Volpe P, Sglavo G, Russo MG, De Robertis V, Penner I, Nappi C. Partial atrioventricular septal defect in the fetus: diagnostic features and associations in a multicenter series of 30 cases. *Ultrasound Obstet Gynecol*. 2009 Sep;34(3):268-73.

- 114) Maruotti GM, *Paladini D*, Napolitano R, Mazzarelli LL, Russo T, Quarantelli M, D'Armiento MR, Martinelli P. Prenatal 2D and 3D ultrasound diagnosis of diprosopus: case report with post-mortem magnetic resonance images (MRI) and review of the literature. *Prenat Diagn*. 2009 Oct;29(10):992-4. Review.
- 115) Van Holsbeke C, Zhang J, Van Belle V, *Paladini D*, Guerriero S, Czekierdowski A, Muggah H, Ombelet W, Jurkovic D, Testa AC, Valentin L, Van Huffel S, Bourne T, Timmerman D. Acoustic streaming cannot discriminate reliably between endometriomas and other types of adnexal lesion: a multicenter study of 633 adnexal masses. *Ultrasound Obstet Gynecol*. 2010 Mar;35(3):349-53.
- 116) *Paladini D*. Fetal micrognathia: almost always an ominous finding. *Ultrasound Obstet Gynecol*. 2010 Apr;35(4):377-84.
- 117) Van Holsbeke C, Van Calster B, Guerriero S, Savelli L, *Paladini D*, Lissoni AA, Czekierdowski A, Fischerova D, Zhang J, Mestdagh G, Testa AC, Bourne T, Valentin L, Timmerman D. Endometriomas: their ultrasound characteristics. *Ultrasound Obstet Gynecol*. 2010 Jun;35(6):730-40.
- 118) *Paladini D*, Greco E, Sglavo G, D'Armiento MR, Penner I, Nappi C. Congenital anomalies of upper extremities: prenatal ultrasound diagnosis, significance, and outcome. *Am J Obstet Gynecol*. 2010 Jun;202(6):596.e1-10. Epub 2010 Feb 20.
- 119) Van Holsbeke C, Van Belle V, Leone FP, Guerriero S, *Paladini D*, Melis GB, Greggi S, Fischerova D, De Jonge E, Neven P, Bourne T, Valentin L, Van Huffel S, Timmerman D. Prospective external validation of the 'ovarian crescent sign' as a single ultrasound parameter to distinguish between benign and malignant adnexal pathology. *Ultrasound Obstet Gynecol*. 2010 Jul;36(1):81-7.
- 120) Espinoza J, Lee W, Comstock C, Romero R, Yeo L, Rizzo G, *Paladini D*, Viñals F, Achiron R, Gindes L, Abuhamad A, Sinkovskaya E, Russell E, Yagel S. Collaborative study on 4-dimensional echocardiography for the diagnosis of fetal heart defects: the COFEHD study. *J Ultrasound Med*. 2010 Nov;29(11):1573-80.
- 121) D'Alessio F, Mirabelli P, Gorrese M, Scalia G, Gemei M, Mariotti E, Di Noto R, Martinelli P, Fortunato G, *Paladini D*, Del Vecchio L. Polychromatic flow cytometry analysis of CD34+ hematopoietic stem cells in cryopreserved early preterm human cord blood samples. *Cytometry A*. 2011 Jan;79(1):14-24.

- 122) Daemen A, Jurkovic D, Van Holsbeke C, Guerriero S, Testa AC, Czekierdowski A, Fruscio R, *Paladini D*, Neven P, Rossi A, Bourne T, De Moor B, Timmerman D. Effect of cancer prevalence on the use of risk-assessment cut-off levels and the performance of mathematical models to distinguish malignant from benign adnexal masses. *Ultrasound Obstet Gynecol.* 2011 Feb;37(2):226-31. doi: 10.1002/uog.8849. Epub 2011 Jan 14.
- 123) *Paladini D*, Sglavo G, Masucci A, Pastore G, Nappi C. The role of 4D ultrasound (STIC + sonoAVC) in the prenatal assessment of atrial morphology cardiosplenic syndromes. *Ultrasound Obstet Gynecol.* 2011 Mar 14. doi: 10.1002/uog.8993.
- 124) *Paladini D*. How to identify the thymus in the fetus: the thy-box. *Ultrasound Obstet Gynecol.* 2011 Apr;37(4):488-92. doi: 10.1002/uog.8854.
- 125) *Paladini D*, Sglavo G, Pastore G, Masucci A, D'Armiento MR, Nappi C. Aberrant Right Subclavian Artery (ARSA). Incidence and correlation with other markers of Down syndrome in 2nd trimester fetuses. *Ultrasound Obstet Gynecol* 2011.
- 126) *Paladini D*, Quarantelli M, Pastore G, Sorrentino M, Sglavo G, Nappi C. Abnormal or delayed development of the Area Membranacea Posterior of the brain: the Blake's pouch cyst. Anatomy, ultrasound diagnosis, natural history and outcome in the fetus. *Ultrasound Obstet Gynecol.* 2012, Mar;39(3):279-87
- 127) Izzo A, Genesio R, Ronga V, Nocera V, Marullo L, Cicatiello R, Sglavo G, *Paladini D*, Conti A, Nitsch L. 40 Mb duplication in chromosome band 5p13.1p15.33 with 800 kb terminal deletion in a foetus with mild phenotypic features. *Eur J Med Genet.* 2012 Feb;55(2):140-4.
- 128) Vassallo M, Maruotti GM, Quarantelli M, Pastore G, *Paladini D*. Choroid plexus carcinoma: prenatal characterization by 3-dimensional sonography and magnetic resonance imaging, perinatal management, and natural history. *J Ultrasound Med.* 2012 Feb;31(2):337-9.
- 129) Ameye L, Timmerman D, Valentin L, *Paladini D*, Zhang J, Van Holsbeke C, Lissoni AA, Savelli L, Veldman J, Testa AC, Amant F, Van Huffel S, Bourne T. Clinically oriented three-step strategy for assessment of adnexal pathology. *Ultrasound Obstet Gynecol.* 2012 Nov;40(5):582-91.
- 130) International Society of Ultrasound in Obstetrics and Gynecology, Carvalho JS, Allan LD, Chaoui R, Copel JA, DeVore GR, Hecher K, Lee W, Munoz H, *Paladini D*, Tutschek B, Yagel S. ISUOG Practice Guidelines (updated): sonographic screening examination of the fetal heart. *Ultrasound Obstet Gynecol.* 2013 Mar;41(3):348-59.



- 131) Di Spiezio Sardo A, Paladini D, Zizolfi B, Spinelli M, Nappi C. Pentalogy of Cantrell: embryofetoscopic diagnosis. *J Minim Invasive Gynecol.* 2013 Mar-Apr;20(2):248-51.
- 132) *Paladini D*, Pastore G, Cavallaro A, Massaro M, Nappi C. Agenesis of the fetal corpus callosum: sonographic signs change with advancing gestational age. *Ultrasound Obstet Gynecol.* 2013 Dec;42(6):687-90.
- 133) *Paladini D*, Tiesi M, Buffi D, Tuo G, Marasini M. Unexplained right atrial enlargement may be a sign of Holt-Oram syndrome in the fetus. *Ultrasound Obstet Gynecol.* 2014 Apr;43(4):475-6.
- 134) *Paladini D*, Quarantelli M, Sglavo G, Pastore G, Cavallaro A, D'Armiento MR, Salvatore M, Nappi C. Accuracy of neurosonography and MRI in clinical management of fetuses referred with central nervous system abnormalities. *Ultrasound Obstet Gynecol.* 2014 Aug;44(2):188-96.
- 135) Salomon LJ, Alfirevic Z, Audibert F, Kagan KO, *Paladini D*, Yeo G, Raine-Fenning N; ISUOG Clinical Standards Committee. ISUOG consensus statement on the impact of non-invasive prenatal testing (NIPT) on prenatal ultrasound practice. *Ultrasound Obstet Gynecol.* 2014 Jul;44(1):122-3.
- 136) *Paladini D*, Di Spiezio Sardo A, Coppola C, Zizolfi B, Pastore G, Nappi C. Ultrasound assessment of the Essure contraceptive devices: is three-dimensional ultrasound really needed? *J Minim Invasive Gynecol.* 2015 Jan;22(1):115-21.
- 137) Di Spiezio Sardo A, Florio P, Nazzaro G, Spinelli M, *Paladini D*, Di Carlo C, Nappi C. Hysteroscopic outpatient metroplasty to expand dysmorphic uteri (HOME-DU technique): a pilot study. *Reprod Biomed Online.* 2015 Feb;30(2):166-74.
- 138) Bellini C, Donarini G, *Paladini D*, Calevo MG, Bellini T, Ramenghi LA, Hennekam RC. Etiology of non-immune hydrops fetalis: An update. *Am J Med Genet A.* 2015 May;167A(5):1082-8.
- 139) *Paladini D*. Additional value of fetal magnetic resonance imaging in the prenatal diagnosis of central nervous system anomalies: a systematic review of the literature and related correspondence. A plea to assess oranges only. *Ultrasound Obstet Gynecol.* 2015 May;45(5):625-6.
- 140) Pinto J, *Paladini D*, Severino M, Morana G, Pais R, Martinetti C, Rossi A. Delayed rotation of the cerebellar vermis: an important pitfall in early second trimester fetal MR imaging studies. *Ultrasound Obstet Gynecol.* 2015 Oct 8. doi: 10.1002/uog.15782. [Epub ahead of print] PMID: 26482947

- 141) *Paladini D*, Alfirevic Z, Carvalho JS, Khalil A, Malinger G, Martinez JM, Rychik J, Gardiner H. Prenatal counselling for neurodevelopmental delay in congenital heart disease. The results of a worldwide survey of experts' attitudes advise caution. *Ultrasound Obstet Gynecol.* 2016 Jan 7. doi: 10.1002/uog.15852. [Epub ahead of print] PMID: 26749377
- 142) Gigliotti AR, De Ioris MA, De Grandis E, Podda M, Cellini M, Sorrentino S, De Bernardi B, *Paladini D*, Gandolfo C. Congenital neuroblastoma with symptoms of epidural compression at birth. *Pediatr Hematol Oncol.* 2016 Mar;33(2):94-101.
- 143) Khalil A, Bennet S, Thilaganathan B, *Paladini D*, Griffiths P, Carvalho JS. Prevalence of Prenatal Brain Abnormalities in Fetuses with Congenital Heart Disease: Systematic Review. *Ultrasound Obstet Gynecol.* 2016 Apr 7. doi: 10.1002/uog.15932. [Epub ahead of print] Review. PMID: 27062519
- 144) *Paladini D*, Alfirevic Z, Carvalho JS, Khalil A, Malinger G, Martinez JM, Rychik J, Ville Y, Gardiner H; ISUOG Clinical Standards Committee. ISUOG consensus statement on current understanding of the association of neurodevelopmental delay and congenital heart disease: impact on prenatal counseling. *Ultrasound Obstet Gynecol.* 2017 Feb;49(2):287-288.
- 145) *Paladini D*, Malinger G, Pilu G, Timor-Trisch I, Volpe P. The MERIDIAN trial: caution is needed. *Lancet.* 2017 May 27;389(10084):2103.
- 146) *Paladini D*, Deloison B, Rossi A, Chalouhi GE, Gandolfo C, Sonigo P, Buratti S, Millischer AE, Tuo G, Ville Y, Pistorio A, Cama A, Salomon LJ. Vein of Galen aneurysmal malformation (VGAM) in the fetus: retrospective analysis of perinatal prognostic indicators in a two-center series of 49 cases. *Ultrasound Obstet Gynecol.* 2017 Aug;50(2):192-199.
- 147) *Paladini D*, Birnbaum R, Donarini G, Maffeo I, Fulcheri E. Assessment of fetal optic chiasm: an echoanatomic and reproducibility study. *Ultrasound Obstet Gynecol.* 2016 Dec;48(6):727-732.
- 148) Tuo G, *Paladini D*, Montobbio G, Volpe P, Cheli M, Calevo MG, Marasini M. Prenatal Echocardiographic Assessment of Foramen Ovale Appearance in Fetuses with D-Transposition of the Great Arteries and Impact on Neonatal Outcome. *Fetal Diagn Ther.* 2017;42(1):48-56
- 149) Wu LH, Xie HN, *Paladini D*, Zheng J, Du L, Lin MF. Azygos Vein Z Scores in Healthy Fetuses and Fetuses With Venous Malformations Related to the Azygos Vein. *J Ultrasound Med.* 2016 Dec;35(12):2563-2574.
- 150) *Paladini D*, Donarini G, Buffelli F, Fulcheri E. Sonographic visualization of in-vivo formation of intervillous (Kline's) hemorrhage. *Ultrasound Obstet Gynecol.* 2017 Jul;50(1):131-132

- 151) Malinger G, *Paladini D*, Pilu G, Timor-Tritsch IE. Fetal cerebral magnetic resonance imaging, neurosonography and the brave new world of fetal medicine. *Ultrasound Obstet Gynecol.* 2017 Dec;50(6):679-680.
- 152) Severino M, Righini A, Tortora D, Pinelli L, Parazzini C, Morana G, Accorsi P, Capra V, *Paladini D*, Rossi A. MR Imaging Diagnosis of Diencephalic-Mesencephalic Junction Dysplasia in Fetuses with Developmental Ventriculomegaly. *AJNR Am J Neuroradiol.* 2017 Aug;38(8):1643-1646.
- 153) *Paladini D*, Pistorio A, Wu LH, Meccariello G, Lei T, Tuo G, Donarini G, Marasini M, Xie HN. Prenatal diagnosis of total and partial anomalous pulmonary venous connection: multicenter cohort study and meta-analysis. *Ultrasound Obstet Gynecol.* 2018 Jul;52(1):24-34.
- 154) Birnbaum R, Parodi S, Donarini G, Meccariello G, Fulcheri E, *Paladini D*. The third ventricle of the human fetal brain: Normative data and pathologic correlation. A 3D transvaginal neurosonography study. *Prenat Diagn.* 2018;38(9):664–672.
- 155) *Paladini D*, Donarini G, Parodi S, Volpe G, Sglavo G, Fulcheri E. Hindbrain morphometry and choroid plexus position in the differential diagnosis of posterior fossa cystic malformations. *Ultrasound Obstet Gynecol.* 2019;54(2):207–214.
- 156) *Paladini D*, Donarini G, Parodi S, Chaoui R. Differentiating features of posterior fossa at 12-13 weeks' gestation in fetuses with Dandy-Walker malformation and Blake's pouch cyst. *Ultrasound Obstet Gynecol.* 2019;53(6):850–852.
- 157) Prayer D, *Paladini D*, Deprest J. Current Controversies in Prenatal Diagnosis 1: Should MRI be performed on all fetuses with mild ventriculomegaly?. *Prenat Diagn.* 2019;39(5):331–338.
- 158) *Paladini D*, Donarini G, Conti A, Constanza De Angelis L, Witte MH, Genesio R, Bernas M, Bellini T, Boccardo F, Ramenghi LA, Bellini C. Early fetal hydropic changes are associated with moderate dilatation of the brain ventricular system: A clue to a possible link between cervical lymphatic engorgement and ventricular dilatation? *Lymphology.* 2019;52(1):11-17.
- 159) Casella A, Moccia S, Frontoni E, *Paladini D*, De Momi E, Mattos LS. Inter-foetus Membrane Segmentation for TTTS Using Adversarial Networks. *Ann Biomed Eng.* 2020 Feb;48(2):848-859.
- 160) De Angelis LC, Bellini T, Witte MH, Kylat RI, Bernas M, Boccardo F, *Paladini D*, Magnano GM, Ramenghi LA, Bellini C. Congenital chylothorax:

Current evidence-based prenatal and post-natal diagnosis and management. *Lymphology*. 2019;52(3):108-125.

- 161) Haratz KK, Oliveira Szejnfeld P, Govindaswamy M, Leibovitz Z, Gindes L, Severino M, Rossi A, *Paladini D*, Garcia Rodriguez R, Ben-Sira L, Borkowski Tillman T, Gupta R, Lotem G, Raz N, Hamamoto TENK, Kidron D, Arad A, Birnbaum R, Brussilov M, Pomar L, Vial Y, Leventer RJ, McGillivray G, Fink AM, Krzeszowski W, Moron AF, Lev D, Tamarkin M, Shalev J, Toov JH, Lerman-Sagie T, Malinger G. Prenatal diagnosis of rhombencephalosynapsis: neuroimaging features and severity of vermian anomaly. *Ultrasound Obstet Gynecol*. 2021 May 4. doi: 10.1002/uog.23660. Online ahead of print.
- 162) Costa A, Ceresa D, De Palma A, Rossi R, Turturo S, Santamaria S, Balbi C, Villa F, Reverberi D, Cortese K, De Biasio P, *Paladini D*, Coviello D, Ravera S, Malatesta P, Mauri P, Quarto R, Bollini S. Comprehensive Profiling of Secretome Formulations from Fetal- and Perinatal Human Amniotic Fluid Stem Cells. *Int J Mol Sci*. 2021 Apr 2;22(7):3713. doi: 10.3390/ijms22073713.
- 163) *Paladini D*, Malinger G, Birnbaum R, Monteagudo A, Pilu G, Salomon LJ, Timor-Tritsch IE. ISUOG Practice Guidelines (updated): sonographic examination of the fetal central nervous system. Part 2: performance of targeted neurosonography. *Ultrasound Obstet Gynecol*. 2021 Apr;57(4):661-671. doi: 10.1002/uog.23616. Epub 2021 Mar 18.
- 164) Casella A, Moccia S, *Paladini D*, Frontoni E, De Momi E, Mattos LS. A shape-constraint adversarial framework with instance-normalized spatio-temporal features for inter-fetal membrane segmentation. *Med Image Anal*. 2021 May;70:102008. doi: 10.1016/j.media.2021.102008. Epub 2021 Feb 19.
- 165) Reply. Malinger G, *Paladini D*, Haratz KK, Monteagudo A, Pilu G, Timor-Tritsch IE. *Ultrasound Obstet Gynecol*. 2021 Jan;57(1):174-175. doi: 10.1002/uog.23564.
- 166) Dell'Orso G, Giardino S, Pierri F, Volpi S, Mesini A, *Paladini D*, Faraci M. Spontaneous pregnancy after hematopoietic stem cell transplantation for chronic granulomatous disease. *Pediatr Blood Cancer*. 2021 Apr;68(4):e28783. doi: 10.1002/pbc.28783. Epub 2020 Oct 28.
- 167) Malinger G, *Paladini D*, Haratz KK, Monteagudo A, Pilu GL, Timor-Tritsch IE. ISUOG Practice Guidelines (updated): sonographic examination of the fetal central nervous system. Part 1: performance of screening examination and indications for targeted neurosonography. *Ultrasound Obstet Gynecol*. 2020 Sep;56(3):476-484. doi: 10.1002/uog.22145.
- 168) Iacomino M, Baldassari S, Tochigi Y, Kośła K, Buffelli F, Torella A, Severino M, *Paladini D*, Mandarà L, Riva A, Scala M, Balagura G, Accogli A, Nigro V, Minetti C, Fulcheri E, Zara F, Bednarek AK, Striano P, Suzuki H, Salpietro V. Loss of Wwox Perturbs Neuronal Migration and Impairs Early Cortical Development. *Front Neurosci*. 2020 Jun 11;14:644. doi: 10.3389/fnins.2020.00644. eCollection 2020.
- 169) *Paladini D*, Finarelli A, Donarini G, Parodi S, Lombardo V, Tuo G, Birnbaum R. Frontal lobe growth is impaired in fetuses with congenital heart disease. *Ultrasound Obstet Gynecol*. 2021 May;57(5):776-782. doi: 10.1002/uog.22127. Epub 2021 Apr 13.

- 170) *Paladini D*, Donarini G, Bottelli L, Rossi A, Coltri A, Fulcheri E. Isolated, persisting, large choroid plexus cysts should warrant neurosonographic follow up. *Ultrasound Obstet Gynecol*. 2020 May 25. doi: 10.1002/uog.22095. Online ahead of print.
- 171) Fiorio P, Donarini G, Fulcheri E, Meccariello G, Tassano E, Amico G, *Paladini D*. Prenatal Diagnosis of an Uncommon 48,XX,+18+21 Karyotype in a Fetus With Malformations Typical of Both Trisomies. *J Ultrasound Med*. 2020 Nov;39(11):2277-2279. doi: 10.1002/jum.15336. Epub 2020 May 15.
- 172) Vena F, Donarini G, Scala C, Tuo G, *Paladini D*. Redundancy of foramen ovale flap may mimic fetal aortic coarctation. *Ultrasound Obstet Gynecol*. 2020 Dec;56(6):857-863. doi: 10.1002/uog.22008. Epub 2020 Nov 13.
- 173) Reply. *Paladini D*; authors. *Ultrasound Obstet Gynecol*. 2020 Jan;55(1):140. doi: 10.1002/uog.21917.
- 174) *Paladini D*, Donarini G, Conti A, Constanza De Angelis L, Witte MH, Genesio R, Bernas M, Bellini T, Boccardo F, Ramenghi LA, Bellini C. Early fetal hydropic changes are associated with moderate dilatation of the brain ventricular system: A clue to a possible link between cervical lymphatic engorgement and ventricular dilatation? *Lymphology*. 2019;52(1):11-17.
- 175) *Paladini D*, Donarini G, Rossi A. Indications for MRI in fetal isolated mild ventriculomegaly... 'And then, there were none'. *Ultrasound Obstet Gynecol*. 2019 Aug;54(2):151-155. doi: 10.1002/uog.20269. Epub 2019 Jul 8.

Update June 2021

